

**PATIENT PRESENTING CLINICAL SIGNS**

Thumper Lindeman History: Chronic intermittent vomiting and constipation and elevated liver enzyme activity and bilirubin. More recent hyporexia and weight loss.

**SPECIES** Physical Examination: Poor body condition.

Feline Urinalysis: N/A.

**BREED** CBC: N/A.

DLH Serum Biochemistry: Elevated liver enzyme activity and bilirubin.

**SEX** Radiographic Findings: N/A.

FS

**ULTRASONOGRAPHIC EXAMINATION OF THE ABDOMEN**

**Urinary System**

AGE 11 years

Full urinary bladder with a thickened and irregular appearance of especially the apical wall. Normal anechoic urine with no sediment or uroliths evident.

**WEIGHT**

2.6 kg

Normal trigone area, proximal urethra, and iliac blood vessels.

Normal iliac lymph nodes. Ureters not visualized.

**INTERPRETED BY**

Remo Lobetti, BVSc,  
MMedVet (Med), PhD,  
Dipl. ECVIM

Normal renal size (right 4.4 cm), echogenic appearance, cortico-medullary differentiation, blood flow, capsule, and pelvis.

**Reproductive System**

N/A.

**Adrenal Glands**

Normal shape, echogenic appearance, size, and position. Left 0.34 cm.

**Spleen**

Normal size (0.9 cm) with a diffuse increased echogenic appearance. Smooth homogenous parenchyma, smooth curvi-linear capsule, and normal vasculature. No evidence of inflammatory, neoplastic, infarction, or infiltrative changes noted.

**Liver**

Normal size with a diffuse hyperechogenic appearance, prominent portal markings, and regular curvilinear capsule. No nodules or masses evident. Full gall bladder containing normal anechoic bile. Normal thickness and appearance of the gall bladder wall. Dilated and tortuous bile duct with hyperechogenic appearance of the surrounding mesentery.

**IMAGING PERFORMED BY**

Dr Donna Markland,  
DVM

**HOSPITAL NAME**

Ladysmith Animal  
Hospital

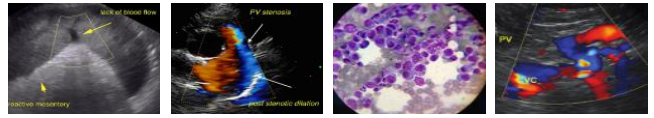
**REFERRING VET**

**INVOICE**

303546

**DATE**

11/11/22



### ***Gastrointestinal***

**PATIENT**

Thumper  
Lindeman

Normal appearance of the stomach, duodenum, small intestine, ileo-cecal junction, and colon with no loss of layering, normal wall thickness and peristalsis, and no distension of the lumen.

**SPECIES**

Feline

### ***Pancreas***

Normal size with a hypoechogenic appearance and irregular capsule. Hyperechogenic echogenic appearance of the mesentery and fat surrounding the pancreas.

**BREED**

DLH

### ***Free Abdomen***

No mesenteric lymphadenomegaly.  
No ascites.

**SEX**

FS

**AGE**

11 years

### **ULTRASONOGRAPHIC FINDINGS**

Primary findings:

**WEIGHT**

2.6 kg

- Hepatopathy.
- Pancreatitis.
- Splenic pathology.
- Urinary bladder thickening.

**INTERPRETED BY**

Remo Lobetti, BVSc,  
MMedVet (Med), PhD,  
Dipl. ECVIM

Secondary findings:

- Dilated bile duct.

### **INTERPRETATION OF THE FINDINGS & FURTHER RECOMMENDATIONS**

Etiologies for the hepatopathy would be cholangio-hepatitis complex, lipidosis, FIP, granulomatous disease, and infiltrative neoplasia.

The appearance of the pancreas is consistent with pancreatitis and would account for the dilated bile duct without any obvious evidence of obstruction.

Etiologies for the spleen would be reactive, hyperplasia, splenitis, and infiltrative neoplasia.

Etiologies for the urinary bladder would be cystitis (bacterial, sterile) and emerging neoplasia.

Further assessment needs to be based on the pending cytology results but would include urinalysis, urine culture, and fPL/PSL assay.

Specific therapy would be dependent on an etiological diagnosis. Symptomatic therapy would be low-fat intestinal diet and ursodiol.

**INVOICE**

303546

**DATE**

11/11/22

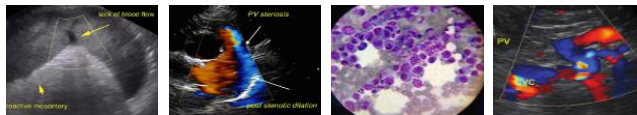
**IMAGING PERFORMED BY**

Dr Donna Markland,  
DVM

**HOSPITAL NAME**

Ladysmith Animal  
Hospital

**REFERRING VET**



**PATIENT**

Thumper  
Lindeman

**SPECIES**

Feline

**BREED**

DLH

**SEX**

FS

**AGE**

11 years

**WEIGHT**

2.6 kg

**INTERPRETED BY**

Remo Lobetti, BVSc,  
MMedVet (Med), PhD,  
Dipl. ECVIM

**IMAGING PERFORMED BY**

Dr Donna Markland,  
DVM

**HOSPITAL NAME**

Ladysmith Animal  
Hospital

**REFERRING VET**

**INVOICE**

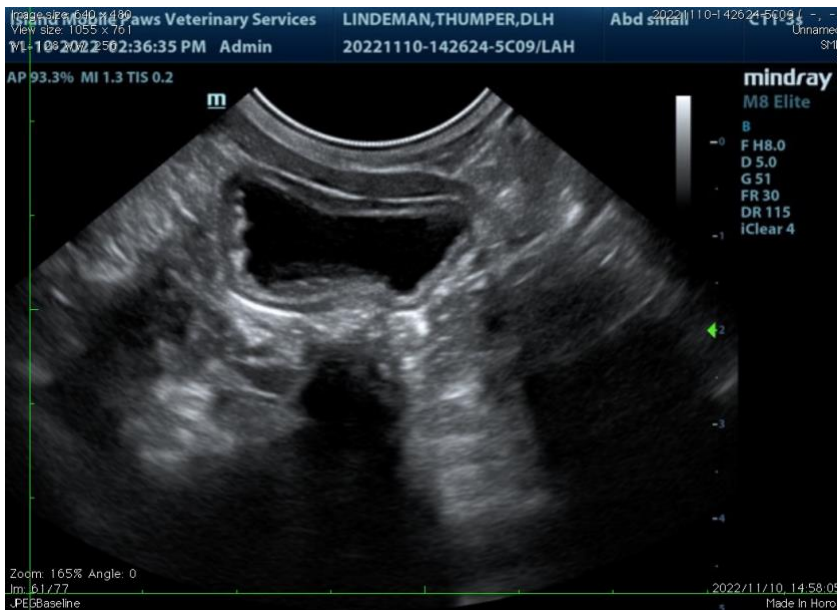
303546

**DATE**

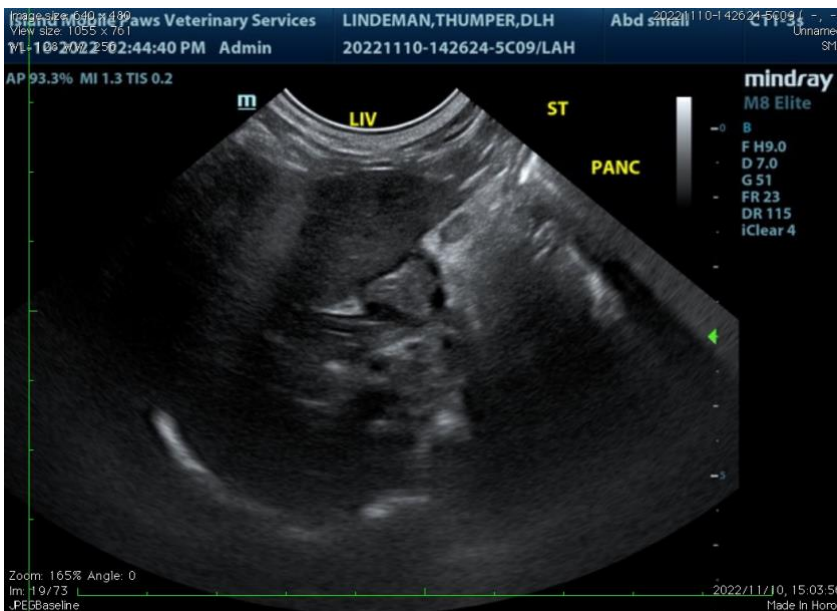
11/11/22

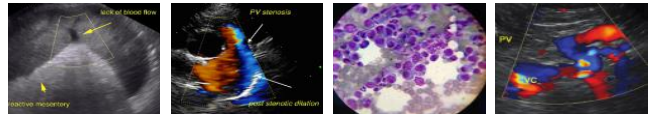
**IMAGES**

**Urinary bladder**



**Pancreas**





**PATIENT**

Thumper  
 Lindeman

**SPECIES**

Feline

**BREED**

DLH

**SEX**

FS

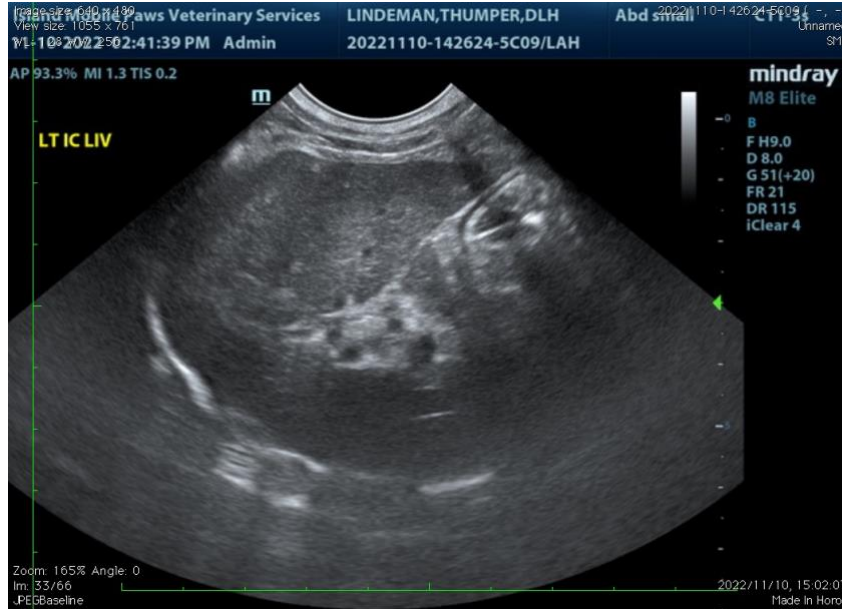
**AGE**

11 years

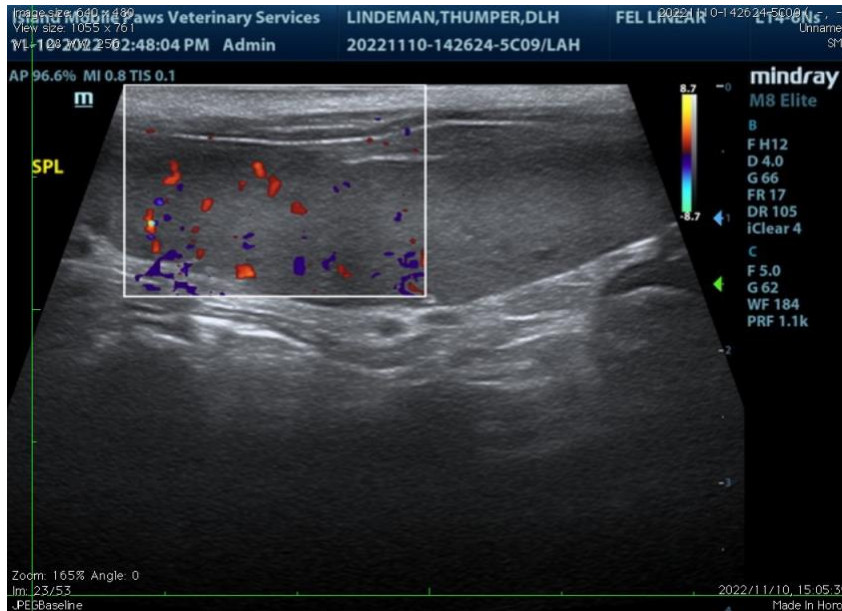**WEIGHT**

2.6 kg

**Liver**



**Spleen**



**INTERPRETED BY**

Remo Lobetti, BVSc,  
 MMedVet (Med), PhD,  
 Dipl. ECVIM

**IMAGING PERFORMED BY**

Dr Donna Markland,  
 DVM

**HOSPITAL NAME**

Ladysmith Animal  
 Hospital

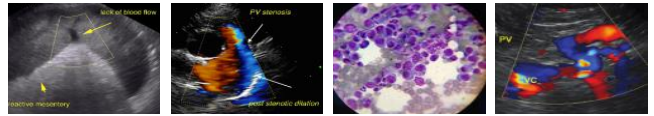
**REFERRING VET**

**INVOICE**

303546

**DATE**

11/11/22



**PATIENT**

Thumper  
Lindeman

**Bile duct/mesentery**

**SPECIES**

Feline

**BREED**

DLH

**SEX**

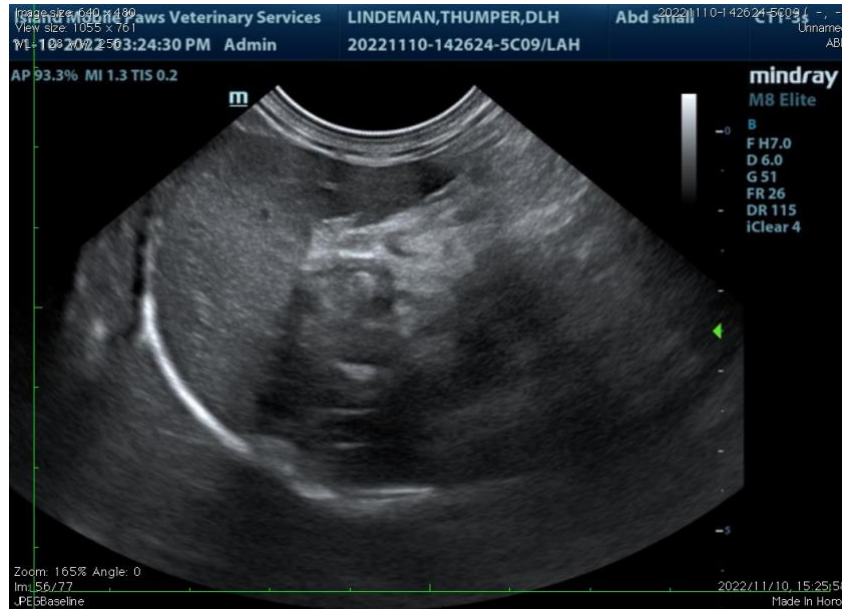FS

**AGE**

11 years

**WEIGHT**

2.6 kg



**INTERPRETED BY**

Remo Lobetti, BVSc,  
MMedVet (Med), PhD,  
Dipl. ECVIM

The information and recommendations provided are based on the images presented by the referring veterinarian. No evaluation can be communicated regarding pathology that was not visible in the image/video clips provided.

Thank you for this referral. If the clinical or image interpretation does not parallel your findings or if I can be of any further assistance please contact me.

**IMAGING PERFORMED BY**

Dr Donna Markland,  
DVM

**Remo Lobetti, BVSc, MMedVet (Med), PhD, Dipl. ECVIM (Internal Medicine)**  
rlobetti@mweb.co.za

**HOSPITAL NAME**

Ladysmith Animal  
Hospital

**REFERRING VET**

**INVOICE**

303546

**DATE**

11/11/22